

30 The Oesophagus

30.1 Foreign bodies in the throat

A patient with a foreign body in the pharynx, or oesophagus, usually knows what has happened and is usually right. It can stick in the tonsils, the vallecula, the pyriform fossa (29-14), or in the lower hypopharynx.

Most fish bones stick in accessible regions, usually the back of the tongue or tonsils. Foreign bodies seldom obstruct in the larynx itself, but typically an affluent, elderly, and often intoxicated diner may get a piece of meat stuck, as a result of which he gasps and collapses.

EMERGENCY TREATMENT FOR CHOKING.

If you are present at the time and the patient is asphyxiating, sit him up, grasp the tongue with gauze, pull it forward, and tell him to keep his mouth open. Then if you can see it, *jam open the jaw*, and hook out the food bolus or foreign body with your finger. If you fail, insert a wide-bore needle (or a blade) through the cricothyroid membrane of the larynx to create an airway: (cricothyroidotomy, 29.15): *this is not to remove the foreign body!* The smaller the patient is the more difficult this will be. Follow this by laryngoscopy, and bronchoscopy (29.14), as soon as possible. *Avoid passing the bronchoscope through the tracheostomy*, which is difficult and dangerous. Only attempt it if the bronchoscope will not pass the cords.

If there is a piece of food in the larynx with persistent choking and inability to talk, try Heimlich's manoeuvre immediately: stand behind the patient, put your fist under the xiphoid and give a short sharp upward thrust, whilst compressing the chest with your arms. This will exert a sudden pressure on the lungs, and may expel the food bolus with a rush of air, with immediate relief. If this fails, or the victim is too obese, sit him propped upon cushions on a chair with its backrest resting against the chest, and push him down forcefully against the back of the chair held rigid by others.

N.B. Do not try a Heimlich manoeuvre on a small child.

If the presentation is early with 'something in the throat' without severe dyspnoea, take a careful history. Where and how severe is the pain? Feel the neck. Is there surgical emphysema? Take radiographs, especially a lateral view. Look for air in the tissues. If a large fish bone has stuck, you may see it, but you will not see a small one. *Do not confuse the hyoid bone (27-19F) for a foreign body!* If there is no convincing evidence that it has lodged in the pharynx, and pain is mild, it probably only scratched the throat and passed on. Treat expectantly. Encourage eating of dry bread. A small sharp object may readily pass through the entire alimentary tract without causing harm.

If you can see a foreign body in the pharynx, or there is air in the tissues, or if for any other reason you suspect it has lodged there, examine the pharynx under ketamine.

Have good suction available. Use a laryngoscope carefully to search the tonsils, the valleculae, and the back of the pharynx. Take the opportunity to have a look at the larynx, even though a foreign body here does cause different symptoms (29.14). Grasp it with Magill forceps, or pull it up with a Foley catheter (30.2).

CAUTION!

- (1) GA and relaxants are dangerous unless you can inflate the lungs. This will mean intubation, which may be tricky.
- (2) Keep the head well down all the time, and the neck extended.

If you do not find it, proceed to oesophagoscopy.

If there is a perforation of the wall of the pharynx, spreading aerobic and anaerobic infection will be dangerous. If there is a large wound, examine it under GA and try to extract the foreign body if still *in situ*. Flexible oesophagoscopy (13.2) is helpful here. If there is cellulitis, necrotizing fasciitis, or an abscess in the neck, open up the soft tissues of the neck carefully. *Beware! The carotid artery may be injured!* Treat with IV chloramphenicol and metronidazole.

30.2 Oesophagoscopy

If you have a flexible endoscope (13.2), use it instead of the rigid instrument as much as possible. It is far less dangerous to the patient!

Passing a rigid oesophagoscope is easier than passing a rigid bronchoscope. An oesophagoscope looks like a bronchoscope except that it has no side tube for oxygen, and no ventilation holes at its distal end, because the patient does not need to breathe through it.

Fortunately, most ingested foreign bodies pass through the oesophagus unless they are sharp or too large, but if they stick, they have to be removed.

Most (90%) stick in the upper 5cm of the oesophagus, just below the *cricopharyngeus* (30-1A) before the oesophagus enters the thorax. This is fortunate, because this is the easiest place from which to remove them. They are commonly coins, buttons, safety pins, or bones.

The patient may have almost no symptoms, or he may be distressed, refuse food, drool saliva, choke, gag, or cough (typically in paroxysms). If he is a child, he may merely 'fail to thrive'. If he is older, he may complain of pain, or the sensation of a foreign body behind the sternum.

If the foreign body is large enough to compress the trachea, he may have stridor, or episodes of cyanosis and recurrent pneumonitis (unusual).

If a foreign body gets stuck at the gastro-oesophageal junction, suspect achalasia (30.6).

OESOPHAGOSCOPY

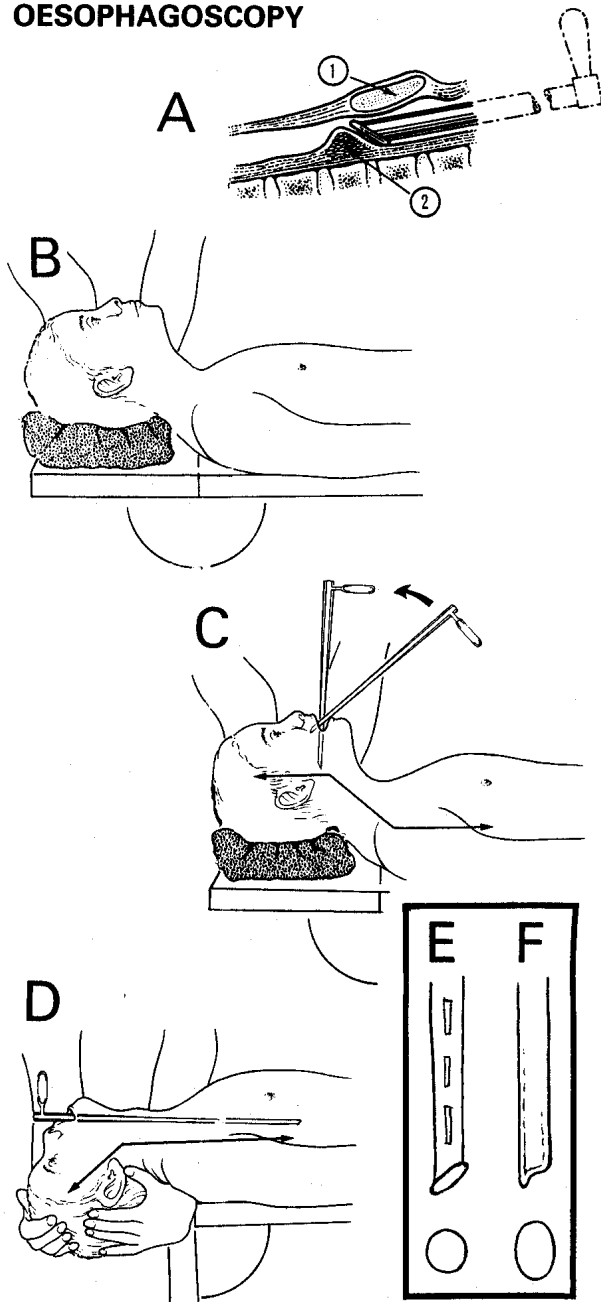


Fig. 30-1 CORRECT POSITION OF THE HEAD FOR RIGID OESOPHAGOSCOPY. A, the difficult part is passing the cricoid cartilage (1) and *cricopharyngeus* muscle (2). This will be easier if you keep the handle of the instrument up, so that it slides over this muscle. B, keep the head on a pillow with the neck flexed and the head extended in the 'sniffing position'. This position will allow you to pass the oesophagoscope as far as the deepest part of the thoracic kyphosis. C, introduce the oesophagoscope obliquely and move it vertically, as it reaches the pharynx. D, if you need to examine the lowest part of the oesophagus (less often necessary), straighten or slightly extend the neck, until he is in the sword-swallowing position. E, a rigid bronchoscope is circular, and has air holes. F, an oesophagoscope is oval, and has none.

Adapted from Dudley HAF (ed) Hamilton Bailey's *Emergency Surgery*, Wright 11th ed 1977 p. 249,251 Figs 22.1,3 with kind permission.

If the patient is very young, or mentally incompetent, there may be no history that he has swallowed anything. Symptoms may have lasted hours or years. The diagnosis is usually obvious, but a foreign body which is missed, can cause persistent dysphagia and loss of weight, so that you may suspect a carcinoma or oesophageal candidiasis.

A TRUE STORY. The examining surgeon at a nurse's training school (St Francis Hospital, Katete, Zambia in its early days): "What instrument would you use for oesophagoscopy?" Enrolled nurse: "A sigmoidoscope". When it was explained that this was wrong, she repeated (correctly) that this was indeed the instrument that she had seen used at her rural hospital! LESSON: If necessary, improvise.

EQUIPMENT needed

OESOPHAGOSCOPE, (a) infant, (b) child, (c) adult, with forceps and suckers that are long enough to go through them. If you do not have an oesophagoscope, you may be able to use a bronchoscope to remove coins from the oesophagus, or dilate a carcinoma before passing a Celestin tube (30-2E). The more protruding beak of a bronchoscope is, however, more likely to perforate the oesophagus.

BOUGIES, oesophageal, neoprene, standard set, alternate sizes only. The old fashioned gum elastic ones are satisfactory.

THE SECRET OF RIGID OESOPHAGOSCOPY IS TO FLEX THE NECK AND EXTEND THE HEAD

RIGID OESOPHAGOSCOPY (GRADE 2.5)

INDICATIONS.

- (1) Removal of foreign bodies.
- (2) Dilation for a benign or malignant stricture.

N.B. For diagnosis, flexible oesophagogastroscopy is much better and safer (13.2) because it does not need GA, and has much less risk of injury to the oesophagus.

RADIOGRAPHS.

Many, but not all, foreign bodies are radio-opaque, but chicken and fish bones for example may be hard to see. Obtain a lateral view as well as the PA.

In the oesophagus coins lie in the coronal plane, so that you see their full diameter in a PA film. In the respiratory tract they lie sagittally, so that you see them from the side.

A barium swallow may be useful, but it makes oesophagoscopy soon afterwards more difficult; diatrizoate meglumine ('gastrografin') is better.

CAUTION!

- (1) Not all foreign bodies are visible on a radiograph.
- (2) If there is a swallowed foreign body that may cause trouble, get a radiograph of the whole abdomen and the pelvis also.

(It's obviously no use performing an oesophagoscopy for something that is already in the stomach!)

N.B. Ultrasound may help deciding if an object is in the oesophagus or bronchus.

PREPARATION.

Keep the patient's head on a pillow throughout. This will flex the neck. Then extend the head on the neck to achieve the 'sniffing position'.

If the foreign body is not sharp, pass a lubricated Foley catheter first using a laryngoscope into the oesophagus past the foreign body under ketamine anaesthesia; inflate the catheter balloon with enough water to occlude the oesophagus, and gently pull it out. The foreign body will come out with it, so you must grasp it quickly with Magill forceps lest it falls down the bronchus instead! Make sure the neck is extended and the patient is 'head down'.

N.B. Do not inflate the balloon with air: the tension in the balloon will not be enough to extract the foreign body. If the Foley catheter is too big, use, if you can, a Fogarty balloon embolectomy catheter. This manoeuvre is much safer than using the oesophagoscope if you are inexperienced.

The same position will allow you to pass the oesophagoscope into the deepest part of the thoracic kyphosis. The most common reason for failure is insufficient flexion of the neck, and extension of the head. The patient needs a GA: ask the anaesthetist to place his endo-tracheal tube on the left side of the mouth. Have an efficient suction machine and tubes ready.

If you need to view the very lowest part of the oesophagus (unusual), straighten, or slightly extend, the neck, so that the pharynx and the oesophagus are in a straight line to let the oesophagoscope pass (the 'sword-swallowing position'). Otherwise, keep it flexed. If your table does not have a headpiece that drops down, ask an assistant to hold the head over the end of the table to control its movement (30-1D): *this is not easy, and is potentially dangerous!*

Beware of the lady with the elaborate towering hairstyle: it will be safer to undo this, or just cut it off, than fail to extend her head.

Make sure suction is available and the light is working properly. Have biopsy forceps and foreign body graspers ready; check that these are long enough to pass through the oesophagoscope!

INSERTION.

Aim the oesophagoscope vertically downwards at the uvula, keeping it at the back of the mouth against the palate. Angle it so as to pass the base of the tongue (aim at the foot of the pedestal of the table). When the larynx comes into view, avoid the midline, and pass it laterally, through one or other pyriform fossa (29-14), to reach the oesophagus, which is again in the midline.

Going through the cricopharyngeus is the difficult part. If you have difficulty, pass a tube or bougie first, and use this to guide the oesophagoscope through.

CAUTION!

- (1) *Never advance the oesophagoscope blind or forcefully*, or you may perforate the oesophagus.
- (2) Keep the lumen of the oesophagus in the centre of your field of view, as you slide the instrument down.

REMOVING A FOREIGN BODY

METHOD.

First try laryngoscopy. You may be able to feel the foreign body with a probe, and remove it with a long clamp. If laryngoscopy and simpler methods fail, pass the oesophagoscope.

As soon as you can see the foreign body clearly (usually a coin, which will reflect the light and shine brightly as a transverse line), pass the biopsy forceps and grasp it firmly.

If it moves distally, withdraw the forceps, pass the oesophagoscope a little further, and try to grasp it again. When you have grasped it, bring it and the oesophagoscope out together.

CAUTION!

(1) *The great danger is perforating the oesophagus:*

(a) usually at the level of the *cricopharyngeus* which keeps the entry closed, or

(b) lower down where the foreign body impacts: *beware the aorta lies at this level!*

(2) Safety pins, bones, and lumps of food, such as meat, should, if possible, be removed by an expert: *they are particularly difficult, and dangerous*. You should try to turn round a sharp object and pull it out with the point held distally, if you can do this safely.

(3) *If you cannot see the lumen of the oesophagus beyond, do not advance the oesophagoscope!*

DIFFICULTIES WITH OESOPHAGOSCOPY FOR REMOVING A FOREIGN BODY

If you do not have an oesophagoscope, you may be able to use a sigmoidoscope. Obviously you must clean it and soak it in disinfectant before use! After you have identified the *cricopharyngeus*, use the obturator to negotiate it.

If a foreign body is too large to remove whole, as with an impacted denture, you may be able to break it and remove the pieces.

If you fail to remove a foreign body and cannot dislodge it distally (*but take great care: this may perforate the oesophagus, especially if the foreign body has sharp edges and is too large to fit inside the endoscope*), you may be able to manipulate it into a bag. If the foreign body is blunt, you may be able to pass a Foley catheter beyond it, inflate the balloon with water and pull it out with that (as above). Otherwise, it will probably need removal, *via* an oesophagostomy, through the side of the neck (30-5).

If, soon after oesophagoscopy, there is pain in the neck, behind the sternum, or in the back, or severe dyspnoea, suspect an OESOPHAGEAL PERFORATION (30.7).

Look for air in the neck, pleural cavity or mediastinum (the earliest sign is a translucent crescent overlying the aortic knuckle) on a chest radiograph.

Consider using some water-soluble contrast medium ('gastrografin' not barium) and taking another film.

Arrange an immediate drainage (if the tear is in the cervical oesophagus, 30-5) or thoracotomy. Delay is likely to be fatal.

If an empyema develops, evacuate all fluid and air, insert intercostal drains, keep nil by mouth, and consider a feeding jejunostomy (11.7): a gastrostomy is less effective because the feed can reflux into the oesophagus).

If the above symptoms are delayed, there is fever and the chest radiograph is normal, suspect MEDIASTITIS. Antibiotic treatment is more likely to succeed. Fashion a temporary oesophagostomy tube drainage in the neck (30-5) and a gastrostomy (13.9) to rest the oesophagus. A feeding jejunostomy (11.7) in addition will allow you better to feed the patient.

If there is a retropharyngeal abscess, drain it (6.8).

If there is an oesophageal stricture, try dilating it (30.3), after extracting all the food accumulated proximally.

30.3 Corrosive oesophagitis & oesophageal strictures

Corrosive oesophageal damage is not uncommon in some communities, as the result of swallowing caustic soda (for making soap), sulphuric (battery) acid, or some other corrosive chemical. The victim is usually a child under 5yrs, or an adolescent; occasionally it is the result of a suicide attempt. It is very useful to perform an oesophagoscopy to assess the initial damage. Often the strictures that result are severe and multiple. Keeping a passage open is vital. You can improvise bougies but remember *rigid dilation is always risky!* Do it with infinite care, otherwise you will perforate the oesophagus, and probably kill the patient. *Do not use balloon dilation.*

Oesophageal damage may also occur after excessive or misplaced injection of sclerosants for varices (13.2)

CORROSIVE OESOPHAGEAL INJURY

THE LATENT STAGE

(N.B. *Acute oesophageal injury is dealt with in Volume 2*)

If there is no severe complication immediately, and the pain and dysphagia improve, the victim may think himself cured. However, during the next 6-12wks, granulation tissue in the oesophagus steadily contracts, and become densely fibrous.

You should try to perform oesophagoscopy within. If possible, use a flexible endoscope (13.2). *Do not try to inspect the whole length of the oesophagus with a rigid instrument:* use this for dilation only, though using a flexible instrument and a guide wire is much safer. Treat with cimetidine or ranitidine to lessen the risk of reflux oesophagitis and further scarring.

Persuade the patient to swallow a piece of fine string attached to a toffee, coated with honey. Keep the other end of the string outside the mouth; the string inside the oesophagus will maintain a lumen, however small, and may help with retrograde dilation later, by acting as a guide along which you can direct a bougie.

If injury to the oesophagus is likely to be severe (you can sometimes tell early by the bleaching caused in the mouth and pharynx), *do not hesitate to construct a feeding gastrostomy* (13.9), which you can use for retrograde dilation.

RETROGRADE OESOPHAGEAL DILATION

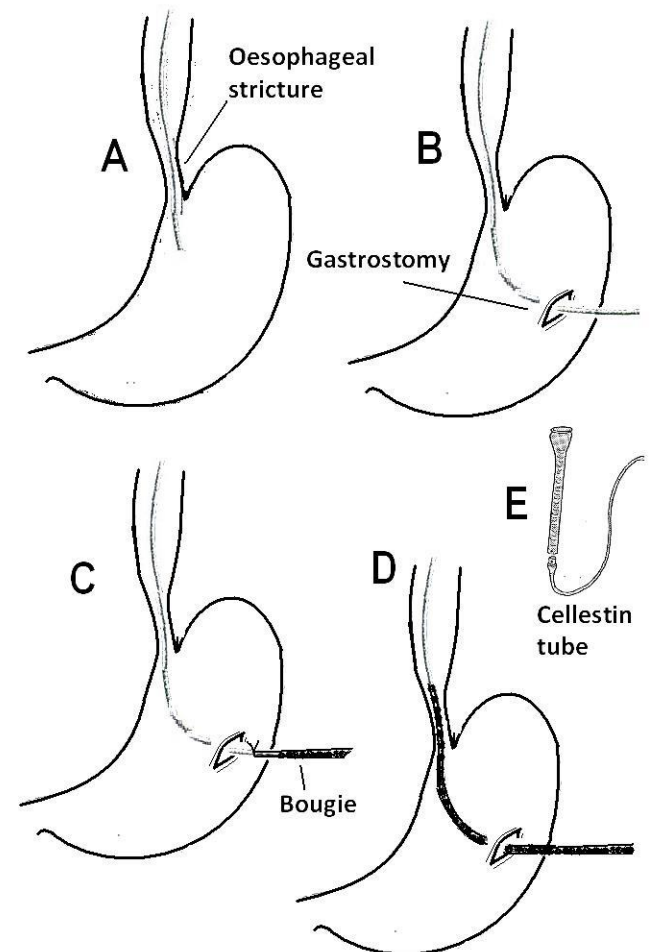


Fig. 30-2 RETROGRADE OESOPHAGEAL DILATION.

A, pass a guidewire through the stricture (if the string is not already in place). **B**, extract it through a gastrostomy. **C**, attach a well-lubricated bougie (dilator). **D**, draw it gently upwards. **E**, attach a Celestin tube in the same way (30.5).

RETROGRADE DILATION (GRADE 3.3)

Dilate the oesophageal track with a bougie in retrograde fashion, using the string already in place (30-2C), 3wks after ingestion of the corrosive and then weekly for 3months: *do not attempt >4mm dilation in one session.*

Then do it monthly for 3months, and every 2months for 6months. If subsequent dilations are easy, remove the string. Perform a barium or 'gastrografin' swallow to monitor progress, and X-ray the chest, especially after a difficult dilation.

Try to provide high-energy liquidized feeds, and keep the oesophagus dilated by eating solid meals. Fizzy carbonated drinks help food go down.

N.B. Do not try to dilate multiple (>3), long (>5cm), or very tortuous strictures, or where there is a tracheo-oesophageal fistula.

THE CHRONIC STAGE

If the oesophagus is not dilated in the latent stage, the stricture will again get worse. The dysphagia gets worse, but because there is no pain, the patient often does not present until there is dysphagia for fluids. There is then hunger, thirst *and* weight loss, and even regurgitation due to distal obstruction in the oesophagus or stomach. The overspill of oesophageal contents, held up above the stricture, may cause aspiration pneumonitis.

Continue to dilate as often as is necessary, until you can pass a large bougie (preferably Ch40), at 4-monthly intervals, over a period of 1yr.

If you cannot pass a bougie by mouth, try the retrograde method (30-2).

REFLUX OESOPHAGEAL STRICTURES

Gastro-oesophageal reflux is common especially in the obese and associated with hiatus hernia; however not everyone who has a hiatus hernia has reflux, and reflux does not necessarily imply a hiatus hernia. If the reflux of acid is severe and continuous, inflammation can lead to stricturing.

A barium swallow may give similar appearances to achalasia (30.6), and so you need endoscopy to differentiate between the two, and to dilate a stricture. This sort is, inevitably, at the lower third of the oesophagus, where dilation is especially hazardous.

DIFFERENTIAL DIAGNOSIS OF BENIGN OESOPHAGEAL STRICTURES

If there is profound wasting, and a barium swallow shows shouldering at the stricture, this is a malignant stricture (30.5).

If there are signs of HIV disease, and especially oral candidiasis, there is likely to be oesophageal *candidiasis* (30.4), which may be so thick as to block the oesophagus. Treat this withazole antifungal agents and fizzy carbonated drinks.

If there is regurgitation and retrosternal pain, without much weight loss, and a barium swallow shows a mega-oesophagus in a 25-35yr old, this is achalasia (primary, or related to Chagas disease: 30.6)

If she is a woman with iron deficiency, and a barium swallow shows a web (38-2D, Plummer-Vinson's syndrome, which is benign).

REMEMBER, DILATION IS EXTREMELY DANGEROUS!

DILATING A BENIGN OESOPHAGEAL STRICTURE (GRADE 3.1)

If you can, use a flexible endoscope (13.2): it is *much* safer.

Otherwise to pass a rigid oesohagoscope, you need a GA and a short-acting relaxant, and intubation for controlled ventilation. Pass the oesophagoscope with care, using one of small diameter first. Suck out residual fluid and advance the instrument under direct vision. If entry is easy, and vision is poor with a narrow instrument, withdraw it, and try a broader one. Continue distally under direct vision, until you see the lesion, continuously sucking out further fluid. *Do not use force.* Note the position of the stricture in cm from the teeth. Note if the stricture is rough (likely to be malignant) or smooth (benign). Take a biopsy. Try to introduce a well-lubricated bougie of size Ch10-12, with a long, strong monofilament threaded to its proximal end; this should pass easily with just a little resistance. If you have a guide wire, with a specially adapted dilator that runs over the guide wire, this will guide you down the proper channel.

Pass bougies of larger diameter gradually up to Ch24-30: some have screws to attach to the previously used bougie so that you do not have to manipulate its passage each time. Finally when the largest bougie has passed, remove the oesophagoscope.

CAUTION! *If the bougie suddenly seems to encounter no resistance at all, you have perforated the oesophagus. Strictures at the lower oesophagus are particularly vulnerable because the oesophagus makes a slight curve when entering the stomach.*

DIFFICULTIES WITH DILATING A BENIGN OESOPHAGEAL STRICTURE

If you fail to pass the bougie, abandon the procedure and try again at the next opportunity: you will be surprised how often it goes easily then!

If the stricture remains impassable, try to arrange an oesophagectomy with remaining stomach or colonic replacement; this is formidable surgery unlikely to be readily available. In the meantime, provide nutrition *via* a gastrostomy (13.9) or jejunostomy (11.7).

If there is severe chest pain, odynophagia even for saliva, and shock, you have perforated the oesophagus (30.7).

30.4 Oesophageal candidiasis

A patient who is immunocompromised with a CD4 level $<200/\mu\text{l}$ is at high risk of developing fungal infestation with *candidiasis*. Whilst it may occur with advanced cancer, steroid inhaler use, long-term antibiotics or chemotherapy, its appearance in the mouth is virtually pathognomonic of HIV disease. It may not be seen in the mouth but be found in the oesophagus. Initially you can see whitish patches which later become confluent and thick, so much so that the whole lumen of the oesophagus may be blocked. Rarely the oesophagus may rupture. If *candidiasis* is limited to the lower oesophagus, symptoms may mimic peptic ulcer disease.

TREATMENT

Fluconazole 100mg od, Miconazole 10ml qid, Nystatin 500000 units qid, or Ketoconazole 200mg od for 2wks is usually effective, if the patient can swallow. Unblocking the oesophagus with fizzy carbonated drinks may be effective; otherwise perform endoscopy (13.2). The endoscope easily gets blocked with thick *candida*, so do these cases last on your list! If this treatment fails, you can try diethylcarbamazine 100-150mg orally bd for 10days.

Relapse is frequent unless you continue a prophylactic dose or start ARV therapy.

30.5 Oesophageal carcinoma

Carcinoma of the oesophagus is one of the most common cancers in Iran, China and parts of South Africa. It is associated with the chewing of tobacco and lime ash (nass), the exposure to opium residues, exclusive eating of maize affected by a fungus, together with vitamin deficiencies; the role of nitrosamines is less well defined. In many parts of the world it is the commonest cause of dysphagia.

EQUIPMENT needed:

TUBES, oesophageal, Celestin, with guide.

TUBES, Procter-Livingstone, 10 mm diameter; length 11, 15, & 19cm, unflanged or flanged (30-3E,F)

STENTS. Self-expanding.

Fig. 30-3 INSERTING A PROCTER-LIVINGSTONE (P-L) TUBE. A, pass the bougie, with a thread attached to it drawn through the oesophagoscope, which is being used to insert a P-L tube. B,C tracheal tube cut to make an improvised oesophageal tube. D, improvised tube in place with end bevelled. E,F, anterior and lateral views of a flanged P-L tube, which prevent upwards slippage; N.B. Some P-L tubes are unflanged.

Kindly contributed by Ian Kennedy.

Presentation usually in a male and >45 yrs, is with:

- (1) Progressive dysphagia, first for solid food and later for thin foods and even water. If you ask the patient to point to the site where food sticks, it will usually correlate well with the site of the lesion.
- (2) Regurgitation; this is common, except in the early stages; the patient may describe it as vomiting.
- (3) Hunger, which can be very distressing.
- (4) Weight loss.
- (5) Coughing on swallowing, due either to a tracheo-bronchial fistula, or to spillage from the oesophagus, through the larynx into the trachea. This happens when the lesion is in the upper or middle $\frac{1}{3}$ of the oesophagus.
- (6) Pain is a late symptom, and is due to spread into the mediastinum.

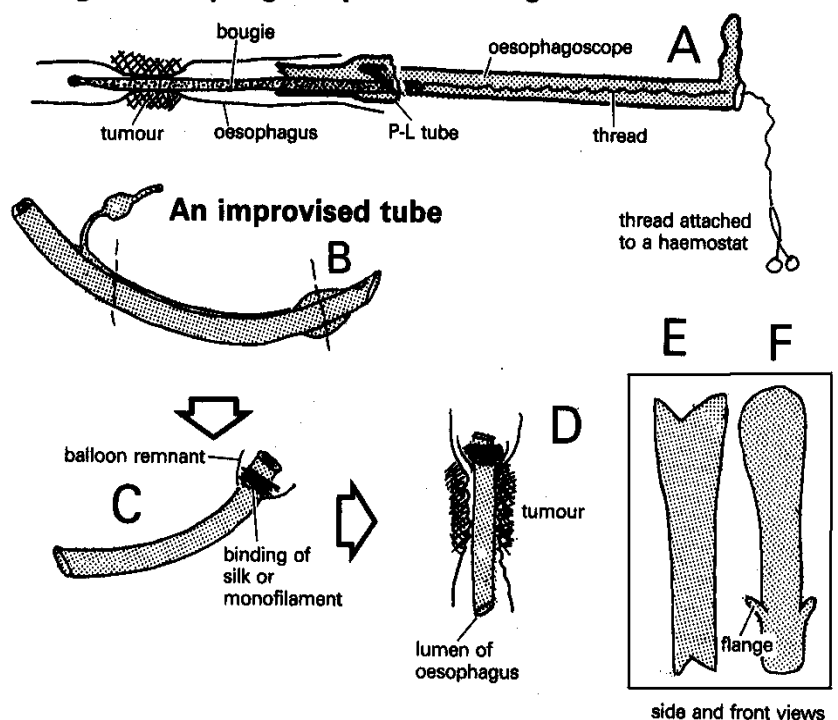
Try to confirm the histology by doing an oesophagoscopy to biopsy and/or dilate the stricture (30.2), and assess its operability. Radiotherapy is a useful palliative. Chemotherapy is not a viable option in most circumstances.

Palliate an inoperable carcinoma with a stent or tube by the antegrade method (e.g. Procter-Livingstone type, 30-3) or by the retrograde method via a gastrostomy (e.g. Celestin type, 30-2). This will allow swallowing mushy food and fluids, and relieve distressing hunger and dehydration. It will allow survival up to 18months in relative comfort, and death may well be from other complications without the tube becoming blocked. Palliative radiotherapy can be given with the tube *in situ*. Do not consider radiotherapy before a tight stricture is dilated: oedema will make it worse initially.

RADIOGRAPHS.

INSERTING AN OESOPHAGEAL STENT

Using an oesophagoscope and a bougie



BARIUM SWALLOW will show a distinctive narrowing, with shouldering of the edges (apple-core lesion, 38.1)

OPERABILITY.

The few cases suitable for oesophagectomy must have:

- (1) A lesion <5cm long on Barium swallow (microscopically, the tumour may extend double this length in each direction), which narrows the oesophagus by <50% and shows no axial deviation.
- (2) No mediastinal widening (no enlarged nodes).
- (3) No deformity of the trachea, carina, or left main bronchus on bronchoscopy.
- (4) No evidence of a tracheo-oesophageal fistula.
- (5) No pneumonia, chronic bronchitis, TB, or HIV disease.
- (6) No significant weight loss (>10%).
- (7) No cardiac disease.
- (8) Good general health, and young age.

Do not refer cases which do not meet these criteria.

CAUTION! *You should not be tempted to create a feeding gastrostomy, which will only prolong the patient's agony, and will not solve the distressing problem of the inability to swallow saliva.*

STENTING FOR CARCINOMA OF THE OESOPHAGUS (GRADE 3.2)

INDICATIONS.

Inability to swallow. Even if there is total obstruction, you may still be able to pass a tube.

CAUTION!

- (1) The earlier the presentation, the easier it will be to pass the tube. *Do not wait until dysphagia is complete:* you may not be able to dilate the stricture.
- (2) There is no substitute for being taught this procedure by an expert.
- (3) *Do not attempt this if the patient has recently had radiotherapy:* the oesophagus becomes very friable and perforation is then a very great risk. Wait for 4wks; *even then the danger is great.*

Check the position and length of the tumour on the barium radiograph, and also note any deviation or fistulae present, which may make placing the tube difficult.

N.B. Using a flexible endoscope (13.2) and placing a stent is much easier and safer for the patient.

Using the rigid oesophagoscope, aim to place a P-L, similar or improvised tube (30-3B,C) antegrade through the dilated oesophageal stricture; choose a tube of the right length (11cm, 15cm or 19cm). Make sure the stricture is dilated to an adequate width to accommodate the tube. Leave the dilating bougie *in situ*, and make sure a strong monofilament thread (fishing wire) is attached to it, so you can pull it out easily if necessary. Lubricate the tube well inside and out, and slide it over the end of the bougie. Guide the tube into the patient's mouth and pharynx with your left hand, and engage the oesophagoscope in the cupped upper end of the tube.

Push both gently over the bougie down the oesophagus. When the tube reaches the tumour, you may feel some resistance. Now push more firmly with a gentle twisting action. You will feel the P-L tube passing through the stricture, until you feel its cup being stopped by the upper end of the stricture. Watch the cm scale on the oesophagoscope, as it passes the teeth, so that the tube rests not >1cm than the distance to the tumour measured previously.

Remove the bougie, untwist the oesophagoscope slightly to disengage it from the cup of the P-L tube. Look down the oesophagoscope to see that the tube is in place. Suck out blood and tumour debris. Remove the oesophagoscope under direct vision.

The P-L tube is unsuitable for very high lesions (<15cm from the incisor teeth), and low lesions (>35cm from the incisor teeth), because of the problem of acid reflux. *The mortality of insertion is c.10%.*

N.B. There are similar, safer and more reliable and lasting expandable stents which can be inserted in the same way, with the appropriate introducer; these are now not so expensive.

If you use a Celestin-type (retrograde) tube, pull it down through an open gastrostomy (30-2C). Occasionally the stricture cannot be dilated from above, but it might be possible from below. *However, the mortality of this procedure is significantly higher (20%).*

POSTOPERATIVELY

Continue IV fluids till oral intake is satisfactory: unless there are problems with the procedure, swallowing is usually possible immediately. Advise the patient, in his enthusiasm to resume eating, to chew his food well. Remember to advise laxatives, as the liquidized food taken subsequently will tend to constipation. It is best to avoid stringy vegetables.

DIFFICULTIES WITH OESOPHAGEAL TUBES

If you make a false passage or tear the stricture, mediastinitis will follow and usually be rapidly fatal within 24hrs. Life without a tube is so intolerable that you will have to take this risk. Surgical intervention is very unlikely to be successful.

If the bougie passes, but the tube will not pass, you may need considerable force, even after what seems like good dilation. Only one diameter (10mm) of P-L tube is made, and it does not pass every stricture. You can make a home-made tube (30-3B,C). Take a soft plastic endotracheal tube of suitable size, cut off the tip with half the balloon. Wind thick silk or nylon under the balloon remnant to make a bulge. Cut the tube long enough for the stricture, and bevel the other end by cutting it obliquely, to make it easier to pass.

With the oesophagoscope in place, pass the improvised tube with long forceps under direct vision until its bulbous end is snug up to the top of the carcinoma. It will be possible to take thick liquids at least.

Or, get a long piece of wire from your workshop which will just pass down the whole length of a Ch18 nasogastric tube. Lubricate it well and pass it through the tube. Pass this wire stylet and tube through the oesophagoscope, through the stricture and into the stomach. Remove the stylet and oesophagoscope. Pass a long nasotracheal tube down the nose, recover its distal end from the throat, and bring it out of the mouth. Push the end of the nasogastric tube through the nasotracheal tube out through the nose. Remove the nasotracheal tube. Tape the nasogastric tube to the cheek. Bandage the elbows in extension with rolled newspaper to prevent removal of the tube on recovery from GA.

N.B. In order of increasing efficacy are: nasogastric, improvised, Celestin, P-L tubes, but by far the best is a self-dilating stent.

CAUTION! *Do not try to pass the wire stylet down on its own.*

If you push the whole tube past the stricture (unusual), you may be able to pull it back with strong forceps. If this fails, leave it: it will pass per rectum!

If the patient regurgitates the tube, this is a nuisance, but not a disaster. If possible, replace it by a flanged tube (30-3E,F). The shorter the tube, the better it works, but the more easily it slips out. If it is too short, the tumour may grow over the end and obstruct it. Flanged tubes are more likely to stay in place.

A tube may displace if the patient vomits after the initial procedure, so keep him sedated with an anti-emetic.

If the tube blocks, try fizzy carbonated drinks to unblock foodstuffs, which are usually the cause; if this fails, perform an OGD or oesophagoscopy (13.2, 30.2).

30.6 Achalasia

Sometimes, in a patient of 25-35yrs, there is dysphagia, regurgitation and retrosternal pain; a Barium swallow will initially show tapering of the distal oesophagus, which looks like a benign stricture; later the proximal oesophagus enlarges and ultimately may become enormous. There is however, no blockage: the defect is in the function of the myenteric Meissner & Auerbach plexuses at the gastro-oesophageal junction.

This may be primary, or arise as a result of infestation by *Trypanosoma cruzi* in Central South America (Chagas disease). In this case, other organs are commonly also affected: the heart in >30%, the pylorus is in 20%, the colon in 15% and the gallbladder in 7%. Squamous carcinoma of the lower oesophagus develops in c.5% of Chagas mega-oesophagus.

You can recognize 3 stages of the disease process:

- (1) *incipient* where the dilation of the oesophagus has not yet started and Barium swallow appearances mimic a benign oesophageal stricture,
- (2) *non-advanced* where dilation is <7cm diameter,
- (3) *advanced* where there is gross dilation >7cm and atony of the oesophagus.

If you can get it, endoscopic injection of 1ml of 20IU *botulinum* toxin in each 4 quadrants at the lower oesophageal sphincter gives improvement in >50% of patients.

INVESTIGATION.

Barium swallow radiography gives a characteristic picture of tapering of the oesophagus in:

- (1) oesophageal dilation
 - (2) mega-oesophagus
 - (3) often with food remnants causing 'filling defects'.
- Oesophagoscopy demonstrates no evidence of an obstructive lesion.

EQUIPMENT.

You should use balloon dilation for the incipient stage. In an endemic area, you should obtain the instrument designed by Pinotti from São Paulo: this is a plastic catheter with a 10cm long heavy metal tip and a cylindrical balloon attached to the body of the catheter (30-2).

N.B. This is not the same as a Sengstaken tube (13-14)

BALLOON DILATION OF INCIPIENT MEGA-OESOPHAGUS (GRADE 2.4)

INDICATION. Incipient mega-oesophagus.

Fast the patient for 12hrs. Sit him upright and spray the oropharynx with 4% lidocaine. Introduce the instrument orally and wait till the patient feels the mercury tip has entered the stomach (30-4A). Inject 50ml water into the balloon (30-4B) and gently pull it up against the cardia (30-4C), so that it is anchored there. Then gradually inject a further 50-250ml water until the patient feels pain (30-4D), keeping it inflated for 5mins.

Then empty the balloon until only 50ml are left, thus leaving the balloon in position. Inflate the balloon twice more at intervals of 30mins, and then remove it.

DIFFICULTIES WITH BALLOON DILATION

If there is bloody vomiting after dilation, suspect a mucosal tear. This should heal spontaneously (30.7); if not re-inflate the balloon with half the volume of water to compress the oesophageal mucosa for 5mins, deflate and observe.

If there is persistent retrosternal pain and dysphagia, suspect an oesophageal perforation. This should not occur if you stop distending the balloon when the patient feels pain. Confirm the perforation with a 'gastrografen' swallow. If present, an urgent laparotomy to close the perforation is necessary (30.7): *delay will be fatal.*

BALLOON DILATION OF MEGA-OESOPHAGUS

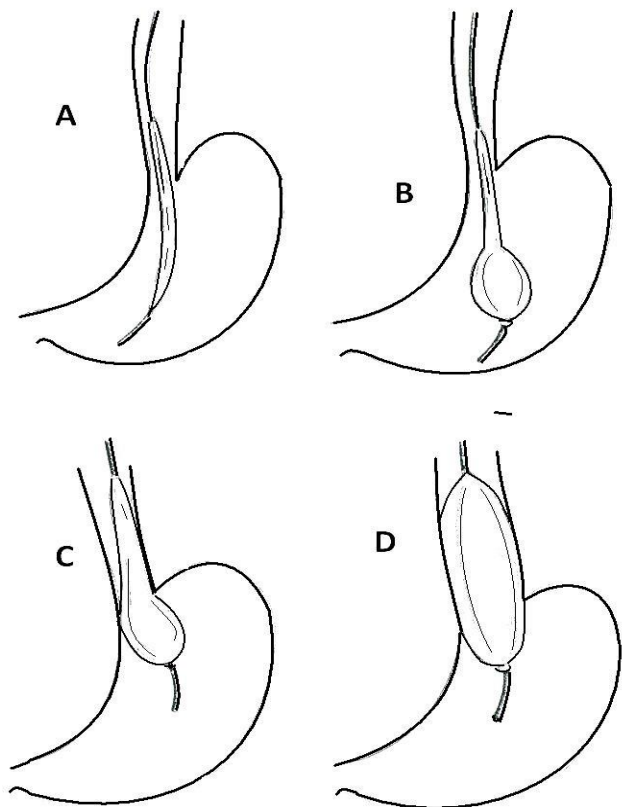


Fig. 30-4 TECHNIQUE OF BALLOON DILATION IN INCIPIENT MEGA-OESOPHAGUS. A, introduction of balloon. B, after injection of the first 50ml water. C, anchor the balloon in the cardia. D, inject water gradually until the patient feels pain. After Cecconello I, Pinotti HW. *South American Trypanosomiasis (Chagas Disease) in Textbook of Tropical Surgery, Westminster 2004, p.986 Fig 221.2.*

If symptoms recur (50% in 5yrs), you can repeat the procedure unless mega-oesophagus has developed

MANAGEMENT OF MEGA-OESOPHAGUS

The *non-advanced* mega-oesophagus <7cm diameter needs an oesophageal myotomy (Heller's operation) with a partial gastric fundoplication (39-6B), to prevent postoperative acid reflux.

The *advanced* atonic mega-oesophagus >7cm diameter needs an oesophagectomy.

30.7 Oesophageal rupture

Apart from iatrogenic damage at oesophagoscopy (30.2), rupture of the oesophagus is rare. It can occur in serious trauma in road accidents (usually head-on collisions), and from penetrating injuries, including foreign bodies. These are likely to be fatal. Rarely, the oesophagus can rupture spontaneously (Boerhaave's syndrome).

IATROGENIC OESOPHAGEAL DAMAGE

Injury to the oesophagus is most likely in the young or old; in the latter because of cervical osteophytes sticking up posteriorly distorting the oesophagus. The laceration occurs in the pharynx or cervical oesophagus just above the *cricopharyngeus* (30-1).

Instrumentation to remove a sharp foreign body, and dilation of strictures are the other common causes of damage further down the oesophagus.

Symptoms will depend on the extent and position of the laceration. A substantial oesophageal injury causes severe pain and quickly develops mediastinitis or peritonitis, which present as septic shock.

Occasionally, a foreign body does not cause full oesophageal rupture. If there is a mucosal tear (Mallory-Weiss syndrome), there is only bleeding; occasionally there is a small breach that allows a leak of organisms. In such cases aggressive treatment and a feeding jejunostomy (11.7) may save the patient. (This is further discussed in Volume 2)

NEVER USE BARIUM IF YOU SUSPECT AN OESOPHAGEAL LEAK

DRAINAGE OF THE CERVICAL OESOPHAGUS

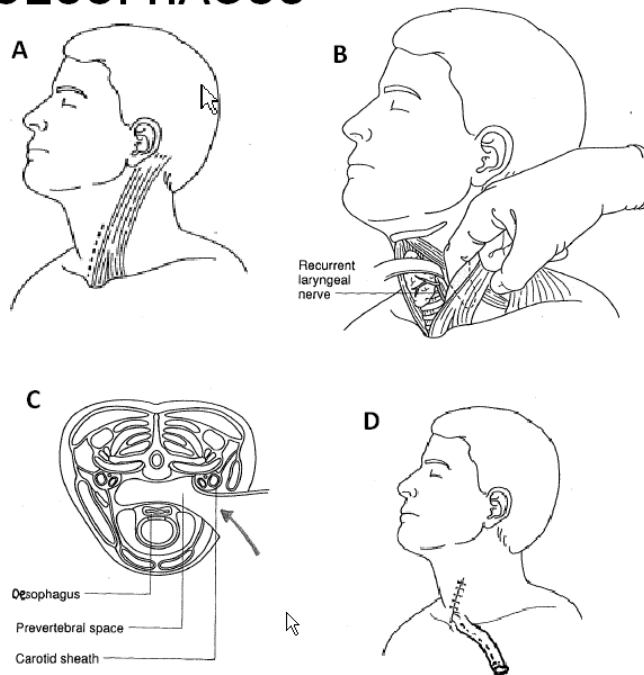


Fig. 30-5 DRAINAGE OF THE CERVICAL OESOPHAGUS. A, make an incision parallel to the anterior border of *sternomastoid*. from the level of the cricoid to the sterna notch. B, retract the *sternomastoid* and carotid sheath laterally with a finger, and the trachea and thyroid medially. C, dissect bluntly along the pre-vertebral fascia avoiding damage to the recurrent laryngeal nerve. Insert a soft tube into the oesophagus if the hole is large, or a drain adjacent to it to pass through the wound. After Greenfield LJ et al. *Surgery, Scientific Principles & Practice, 2nd ed 1997 Lippincott-Rowen p.720 Fig 19-25.*

SPONTANEOUS OESOPHAGEAL RUPTURE (Boerhaave's Syndrome)

The patient, who is usually 20-40yrs, vomits after a heavy meal, and has an intense pain in the abdomen and left (rarely the right) chest radiating to the neck. He is intensely thirsty, but sips of water make the pain worse. Feel and listen with a stethoscope for surgical emphysema (a fine crackling) in the neck or chest. Check for absent breath sounds or hyper-resonance in the left chest. The upper abdomen may be rigid.

RADIOGRAPHS show air in the mediastinum and soft tissues of the neck (usually the left side) and a pleural effusion occasionally with a pneumothorax. Confirm a rupture by repeating the radiograph after ingestion of 10-20ml of 'gastrografin'. This may show a leak.

N.B. Do not use Barium as this may cause severe soft tissue inflammation.

The main differential diagnosis is a perforated peptic ulcer, but here the pain comes before the vomiting. When the oesophagus ruptures, the pain comes with vomiting. Other differential diagnoses include myocardial infarction, spontaneous pneumothorax, and acute pancreatitis.

CAUTION! Early on there are no clinical or radiographic signs in the chest; these come later when treatment may be too late. Confirm the perforation with a 'gastrografin' swallow.

Resuscitate with IV fluids and pass a nasogastric tube (check radiologically that it is not in the mediastinum). Keep the patient nil orally, start IV chloramphenicol and metronidazole antibiotics and insert bilateral chest drains.

If the perforation is in the distal oesophagus, within 12hrs of the perforation, perform a GASTRIC OESOPHAGEAL PATCH (GRADE 3.4).

METHOD

Make an upper midline laparotomy, extending the incision, if necessary, as a T in the subcostal region. Pull down the stomach to expose the lower oesophagus. Divide the short gastric arteries to free up the gastric fundus. The oesophageal tear is usually longitudinal just above the oesophago-gastric junction, slightly on the left. Close it with a diamond-shaped stomach patch. Put a continuous suture along the left edge of the oesophageal rupture and the right edge of the gastric patch you have outlined (30-6A). Then place several loose interrupted sutures along the right edge of the oesophageal rupture and the left edge of the gastric patch. Pull these sutures tight and tie them. Now wrap some of the posterior wall of the stomach round the oesophagus as in a fundoplication (30-6B), and suture the posterior gastric wall around the front of the oesophagus to the anterior gastric wall, allowing enough room for the oesophagus within. Cover the repair with omentum if you can.

Alternatively, for a higher perforation, use a piece of diaphragm to patch the hole: it has a good supply and you can readily make a pedicle of this (but remember its length should not be >2 times its width).

If the perforation is higher up still a neck exploration or thoracotomy, oesophageal repair and mediastinal drainage will be needed, which may well be impossible to organize. You might just save the patient by draining the upper oesophagus in the neck (30-5) and performing a gastrotomy (13.9) and/or jejunostomy (11.7).

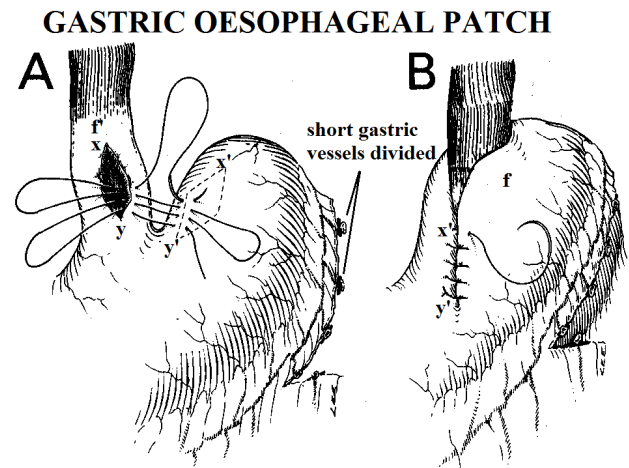


Fig. 30-6 PATCH OF A DISTAL OESOPHAGEAL RUPTURE
A, use the stomach, so that the tear, xy, is covered by x'y'. B, the gastric fundus, f, then comes to f'. Free part of the posterior wall, by dividing the short gastric vessels, and so make a wrap round the oesophagus. After Dudley HAF (ed) Hamilton Bailey's *Emergency Surgery*, Wright 11th ed 1977 p.252 Fig. 22.4, with kind permission

OESOPHAGEAL TEAR (Mallory-Weiss Syndrome)

Following a severe bout of vomiting, a patient may suddenly produce fresh blood in the vomitus. Importantly, the vomiting starts without blood in it, unlike the haematemesis of a peptic ulcer. This is more likely to occur if there is a blood clotting disorder, or the patient is taking anti-coagulants.

The cause is a small laceration of the mucosa of the lower oesophagus; it normally heals spontaneously, once the vomiting has stopped. You can then not usually see it at subsequent endoscopy.

Distinguish the oesophageal tear from varices (13.6).

N.B. A more substantial tear may cause problems described above.